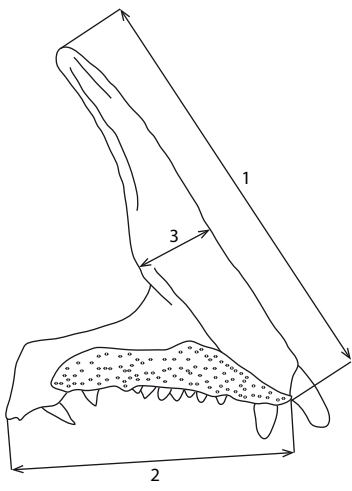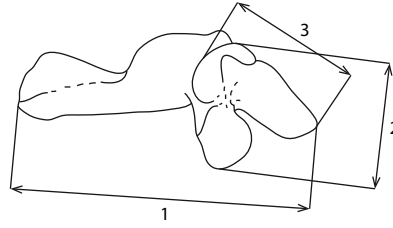
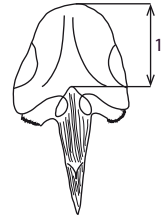


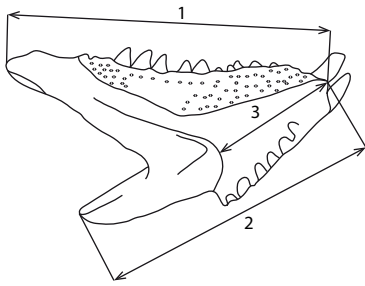
PREMAXILLARY



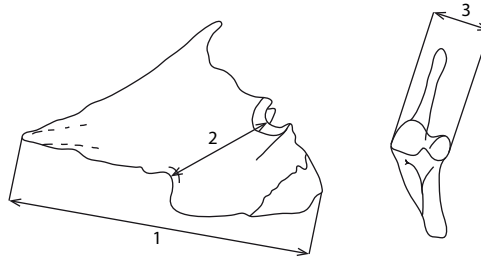
MAXILLARY



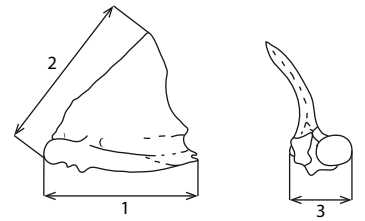
VOMER



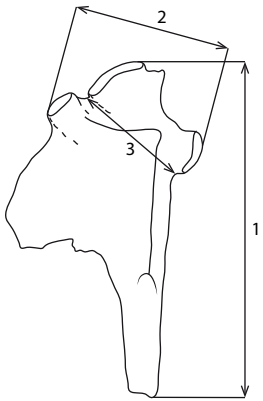
DENTARY



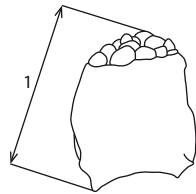
ARTICULAR



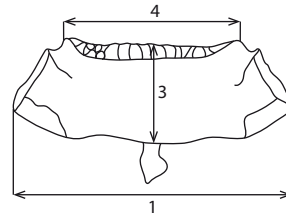
QUADRATE



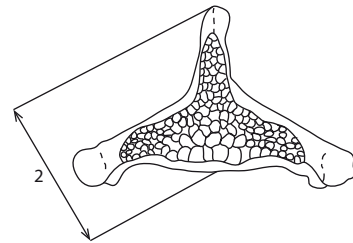
HYOMANDIBULAR



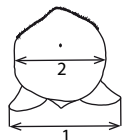
UPPER PHARYNGEAL



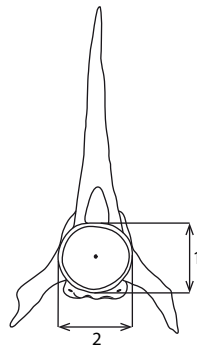
LOWER PHARYNGEAL



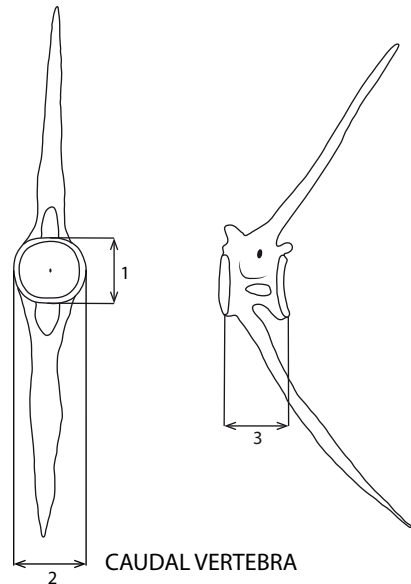
OPERCLE



BASIOCCIPITAL



PRECAUDAL VERTEBRA



CAUDAL VERTEBRA