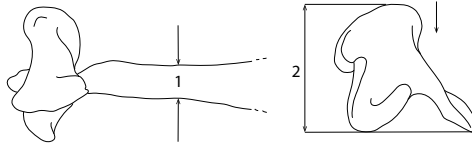
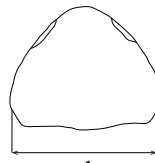


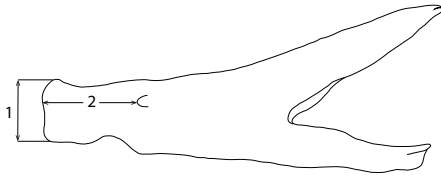
PREMAXILLARY



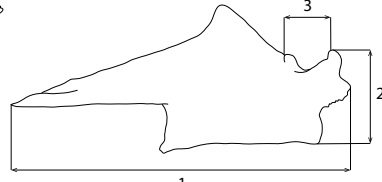
MAXILLARY



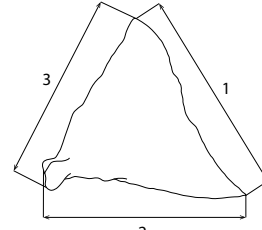
VOMER



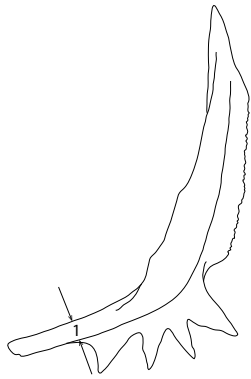
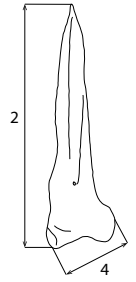
DENTARY



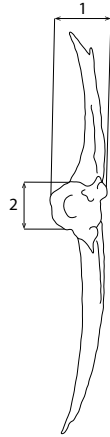
ARTICULAR



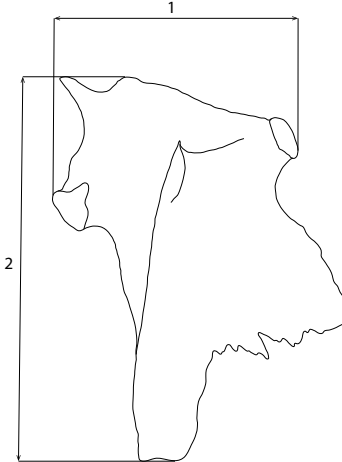
QUADRATE



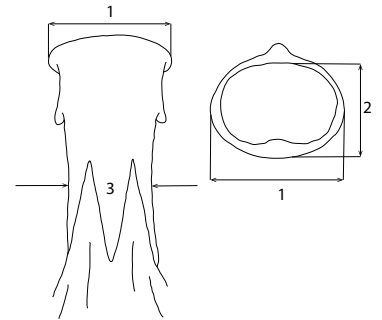
PREOPERCLE



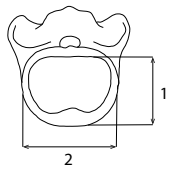
OPERCLE



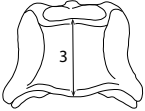
HYOMANDIBULAR



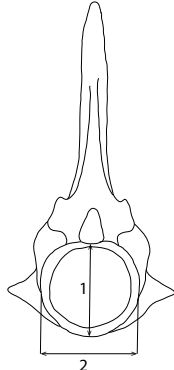
BASIOCCIPITAL



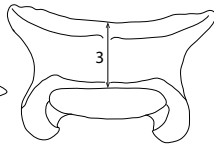
1st PRECAUDAL VERTEBRA



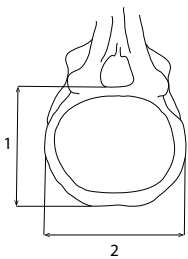
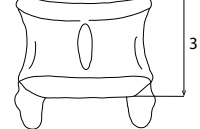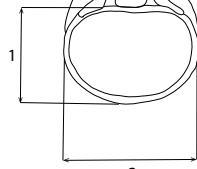
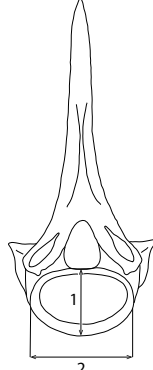
2nd PRECAUDAL VERTEBRA



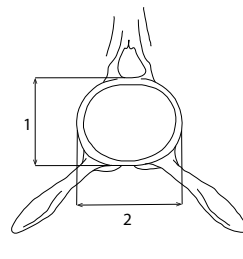
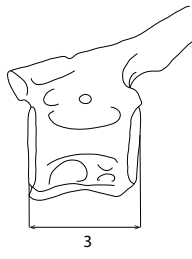3rd PRECAUDAL VERTEBRA



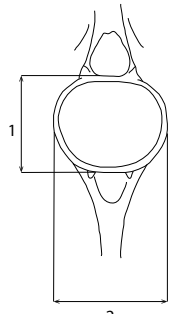
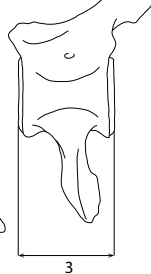
4th PRECAUDAL VERTEBRA



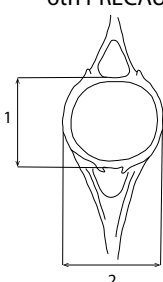
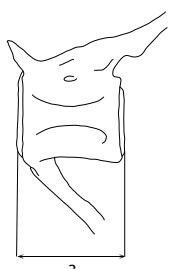
6th PRECAUDAL VERTEBRA



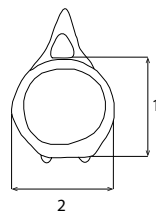
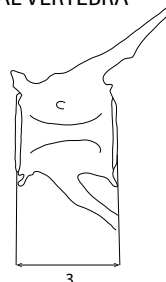
10th PRECAUDAL VERTEBRA



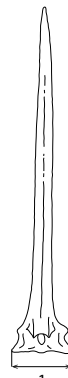
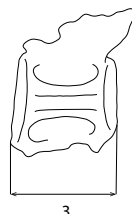
4th CAUDAL VERTEBRA



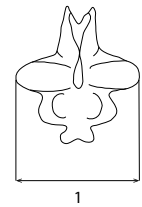
9th CAUDAL VERTEBRA



13th CAUDAL VERTEBRA



1st DORSAL SPINE



ANAL PTERYGIOPHORE