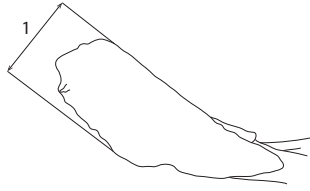
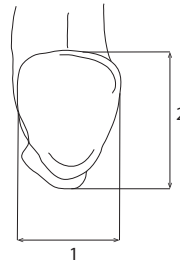


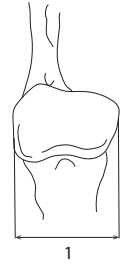
MESETHMOID



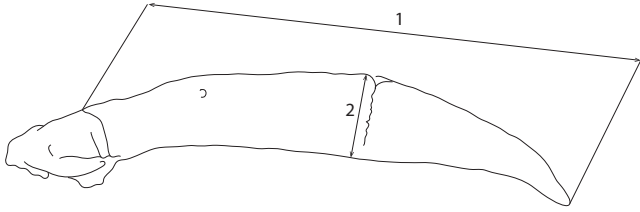
DENTARY



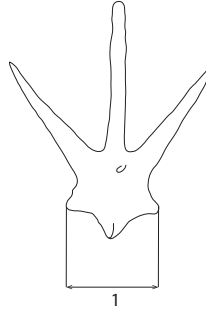
ARTICULAR



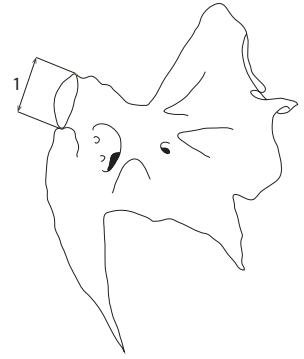
QUADRATE



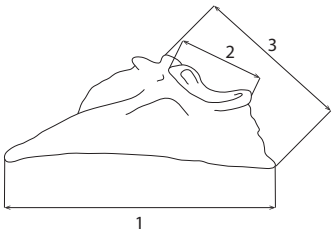
EPI-CERATOHYAL



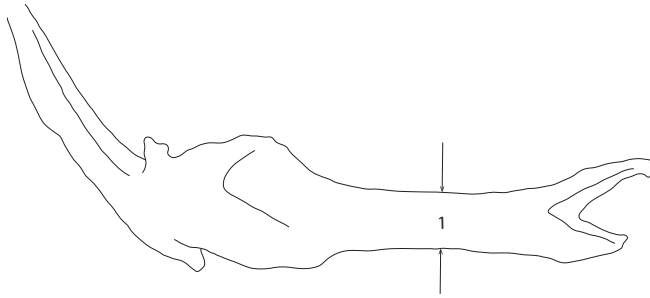
UROHYAL



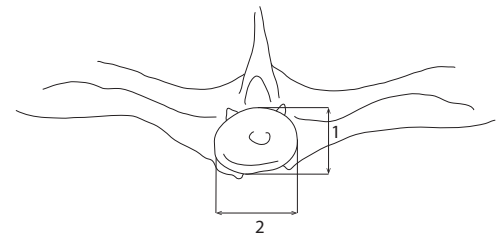
HYOMANDIBULAR



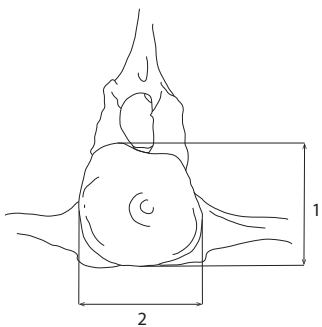
OPERCLE



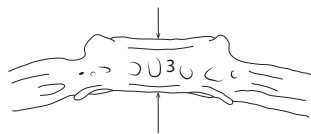
CLEITHRUM



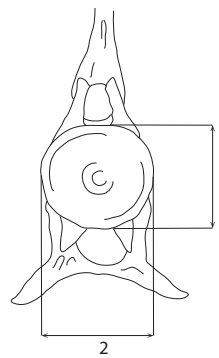
WEBERIAN APPARATUS



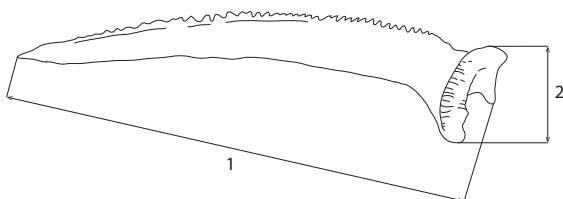
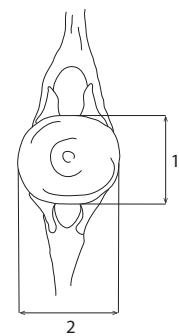
1st PRECAUDAL VERTEBRA



10th PRECAUDAL VERTEBRA



8th CAUDAL VERTEBRA



PECTORAL SPINE

