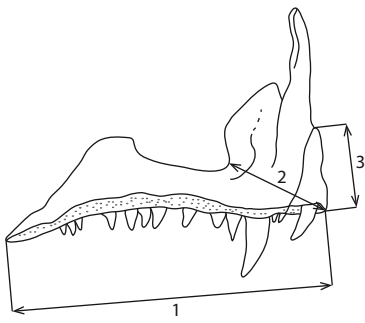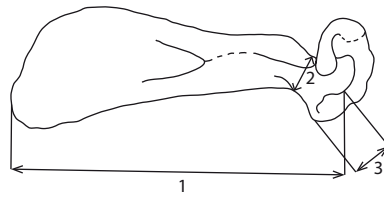
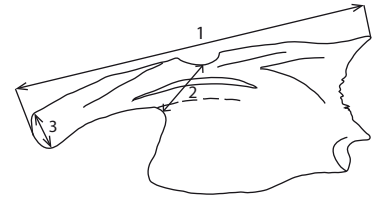


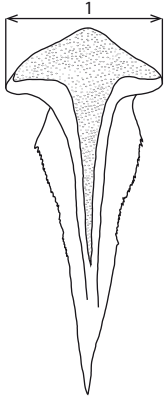
PREMAXILLARY



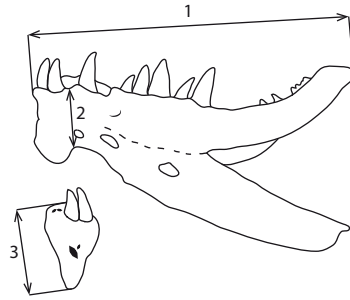
MAXILLARY



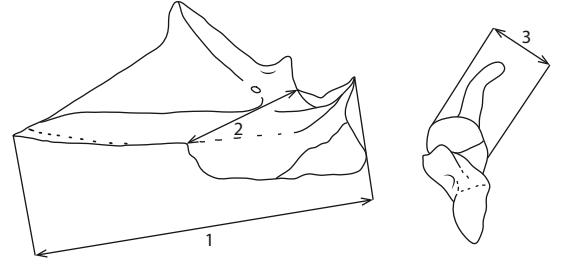
PALATIN



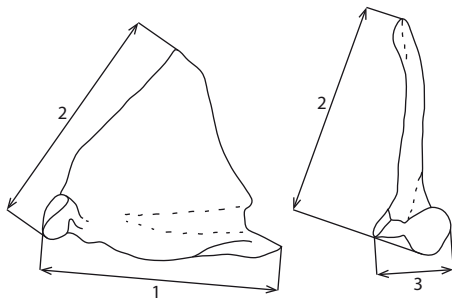
VOMER



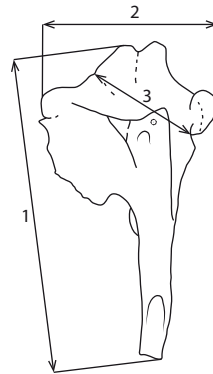
DENTARY



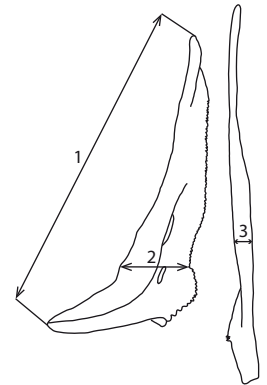
ARTICULAR



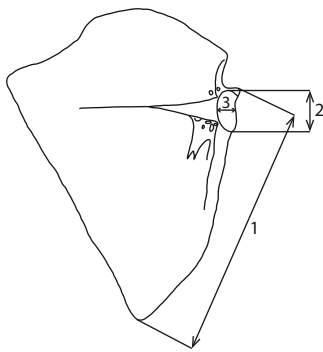
QUADRATE



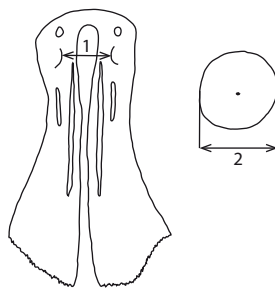
HYOMANDIBULAR



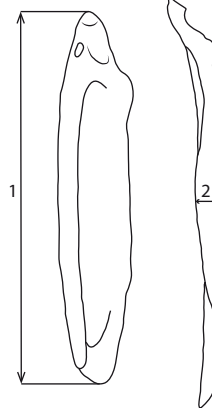
PREOPERCLE



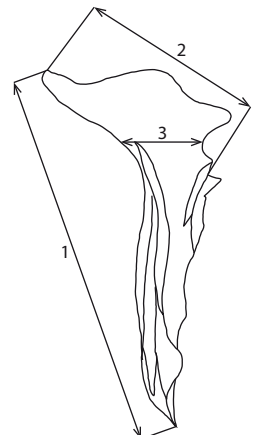
OPERCLE



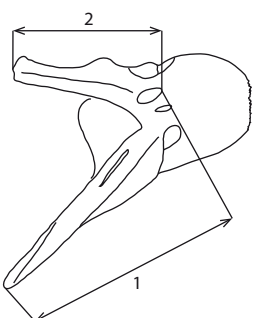
BASIOCCIPITAL



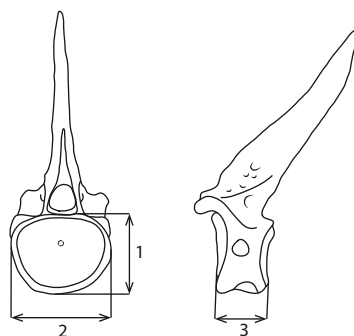
SUPRACLEITHRUM



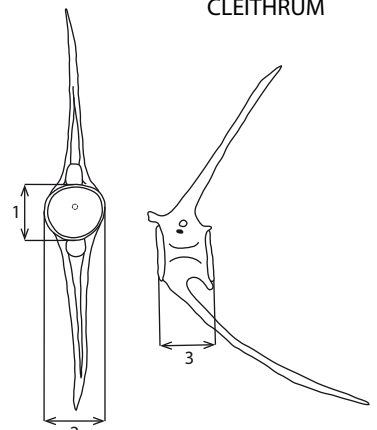
CLEITHRUM



POST TEMPORAL



3rd PRECAUDAL VERTEBRA



3rd CAUDAL VERTEBRA