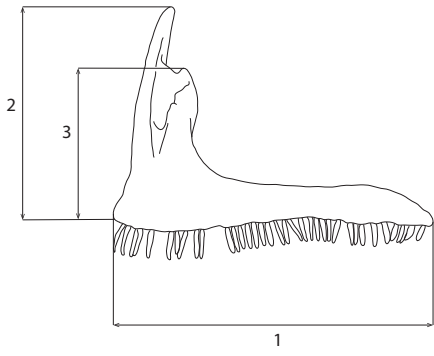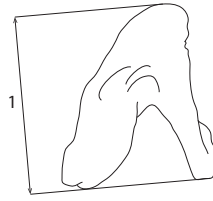
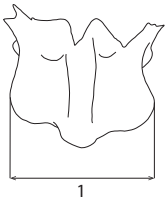


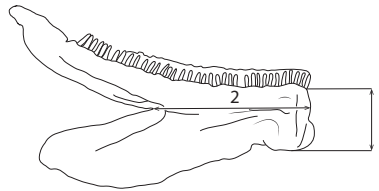
PREMAXILLARY



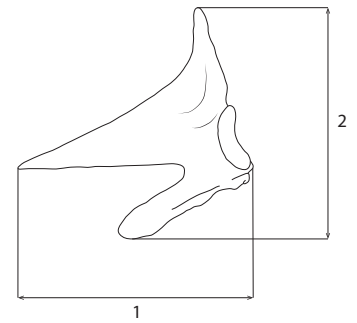
MAXILLARY



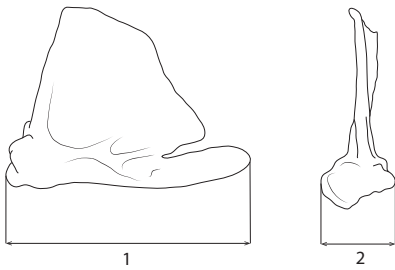
VOMER



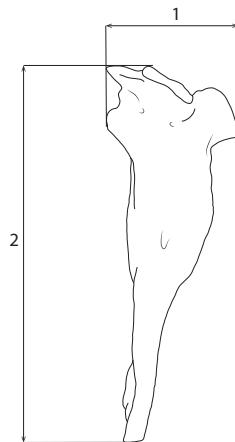
DENTARY



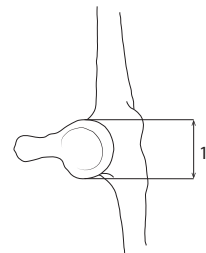
ARTICULAR



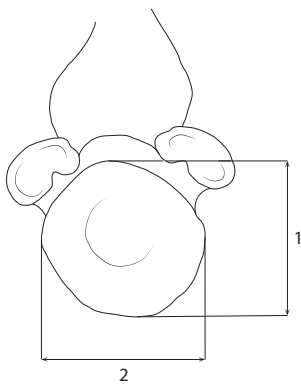
QUADRATE



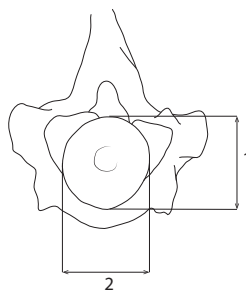
HYOMANDIBULAR



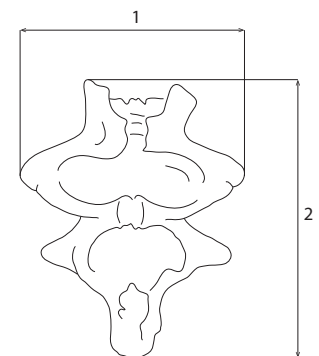
OPERCLE



BASIOCCIPITAL



1st PRECAUDAL VERTEBRA



ANAL PTERYGIOPHORE